
**ISSN Print:** 2394-7489
**ISSN Online:** 2394-7497
IJADS 2022; 8(3): 10-17

www.oraljournal.com
Received: 09-08-2022
Accepted: 16-09-2022

**Dr. Vidushi Koul**
MDS, Private Practitioner, Department of Orthodontics and Dentofacial Orthopaedics, Himachal Dental College, Sundernagar, Himachal Pradesh, India

**Dr. Rohit Saini**
MDS, Private Practitioner, Department of Prosthodontics, Crown and Bridge, Himachal Dental College, Sundernagar, Himachal Pradesh, India

**Dr. Parishrut Nadda**
MDS, Senior lecturer, Department of Orthodontics and Dentofacial Orthopaedics, Himachal Dental College, Sundernagar, Himachal Pradesh, India

**Corresponding Author:**
**Dr. Vidushi Koul**
MDS, Private Practitioner, Department of Orthodontics and Dentofacial Orthopaedics, Himachal Dental College, Sundernagar, Himachal Pradesh, India

# Evaluation of hard and soft tissue changes after en-masse retraction using orthodontic mini-implants: An *in-vivo* study

**Dr. Vidushi Koul, Dr. Rohit Saini and Dr. Parishrut Nadda**

**DOI:** https://doi.org/10.22271/oral.2022.v8.i4a.1619

**Abstract**
**Introduction:** The procedures used for closing the extraction space results in the correction of proclination of incisors, reduction in overjet and elimination of extraction sites. This space closure has been achieved using different mechanics but most recently orthodontic mini-implants (TAD's) have been used efficiently.
**Aim:** To evaluate the skeletal, dental, soft tissue changes and amount of anchor loss in the treatment outcomes using orthodontic mini-implants.
**Materials and Methods**: 25 subjects with Class I bimaxillary protrusion were selected from the patients visiting the department of orthodontics for seeking orthodontic treatment. In all the patients, after extraction of the 1st premolars, retraction was carried out by using mini implants in the maxillary arch.
**Results**: Significant retraction was achieved in all the cases with minimum anchorage loss and significant improvement in patient's profile.
**Conclusion:** Orthodontic mini-implants have revolutionized the orthodontic world and have been an effective way of achieving desired tooth movement in an effective way.

**Keywords:** Orthodontic mini implants, En masse retraction, bimaxillary protrusion

## Introduction
Orthodontic clinician's world revolves around the diagnosis and planning an appropriate treatment which requires a thorough knowledge of biomechanical principles necessary to achieve an ideal occlusion. Extraction space closure can be achieved clinically either by individually retracting the canine in the extraction space which is known as segmental retraction or by retraction of the entire anterior segment simultaneously which is known as en masse retraction [1]. The ideal mechanics are the one in which maximum anchorage is preserved, minimum patient cooperation is needed and the treatment time is less.
In recent years, the concept of using orthodontic mini-implants has been widely accepted as a successful alternative for obtaining required treatment results like maximum anchorage in orthodontic treatment [2]. These mini implants have improved the overall treatment results as they allow treatment to be completed successfully without any anchorage loss and require minimal patient cooperation. Even though orthodontic mini-implants have been utilized for conserving anchorage, the exact amount of anchorage preservation produced with its use has not been studied extensively [3]. So, the aims and objectives of the present study were to assess the skeletal, dental, soft tissue changes and amount of anchor loss by using orthodontic mini implants.

## Aims and Objectives
1. To evaluate the amount of anchor loss by using orthodontic mini-implants.
2. To assess the skeletal, dental and soft tissue changes in the treatment outcomes by using orthodontic mini-implants.

## Material and Method
The study was conducted on the subjects who visited the department for seeking orthodontic

treatment. Informed consent was taken from the patient, parent or guardian. The patient's medical history was reviewed before conducting the study. Proper case history and clinical examination was done for every patient.

**Inclusion criteria**

1. Medical and dental history was taken to rule out any systemic disorders.
2. The age of the patients was not less than 13 years in order to minimize altered results due to growth changes.
3. Absence of any missing teeth (Third molar excluded)
4. Minimum crowding in the maxillary arch.
5. Anchorage Requirements: Type A.
6. Extraction of first premolars.
7. Average growth pattern.
8. Patients with bimaxillary protrusion with Angle's Class I malocclusion and ANB° of 2-4 degrees, with the proclination of maxillary incisors less than 35° were selected.

**Exclusion criteria**

1. Patients with trauma or craniofacial anomalies.
2. Congenitally missing or impacted teeth in the anterior segment.
3. Subjects with severe anterior malocclusions and skeletal class II and III malocclusion
4. Patients with Cleft lip and palate.

Bonding was done for each patient and they were treated with MBT 0.022 x 0.028 inch slot. After initial levelling and alignment in all the patients, 0.019 x 0.025 inch stainless steel arch wires were placed in both maxillary and mandibular arches.

**Mini implant placement**

**Fabrication of surgical guide**:

A wire guide was made from a rectangular wire segment of 0.019x 0.025 inch stainless steel and helix of 2–3 mm diameter was made at the centre of the wire, three helices were used as they were helpful in determination of the appropriate site as compared to single helix and also with the use of more wire component stability was more.[4]The wire guide was soldered onto the arch wire between the first molar and the second premolar on the buccal side using standard soldering procedure as shown in Figure 1. A radiovisiograph was taken to confirm the correct position of the helices for the insertion of mini-implant as shown in Figure 2.

**Method of mini implant placement (Figure 3-6)**

The mini-implant was checked for external damage before use and it was sterilized using an autoclave at 121 degree centigrade at 15 lbs. pressure for 20-30 minutes. After selection of implant location with a radiovisiograph and a surgical guide and achieving appropriate local anesthesia, soft tissue thickness was measured using a periodontal probe. The preferable height of insertion was between free and attached gingiva. The self-drilling mini-implant was inserted through the helix of the guide in the desired direction. Clockwise rotation of the mini-implant using a manual driver was performed [5] After three-fourth of the mini-implant was placed in, a radiovisiograph was taken to confirm the correct position of the mini implant insertion as shown in Figure 3. The wire guide was disengaged and then the mini-implant was completely inserted as shown in Figure 4.

In the present study, the anatomical site of insertion for placement of implant was between the second premolar and first molar in the maxillary arch. The height of the mini implant was kept around 4-6mm in the attached gingiva[6]. The head of the mini-implant was left protruding through the gingiva allowing immediate application of force. Mini implant of 1.5 mm diameter and 8mm length was placed at $45^0$ to the long axis of the proximal tooth. J hooks were soldered distal to the lateral incisor on 0.019"x 0.025" stainless steel arch wire such that the height of the mini-implant and J hook were same, so that only horizontal force was applied for retraction and no additional intrusive or extrusive forces were applied. An elastomeric module with ligature wire of 0.009 inch was tied between the J hook and to the head of the mini-implant to reinforce the anchorage as shown in Figure 6. The patient was recalled after every month and after evaluating the amount of space closure, a new elastomeric module with ligature wire was placed.

Lateral cephalograms were taken for all the patients, both before the start of treatment (T1) and at the end of the retraction process (T2) in all the patients. A single investigator traced the landmarks in all the radiographs using lead pencil on an acetate sheet of 0.003 inch thickness. The pterygoid vertical plane, Sella- nasion plane and Frankfort horizontal plane were used as reference planes for measuring the linear and angular measurements that were done both at start of the treatment and at the end of the retraction process as shown in Figure 5(A&B) and Table 1.

**Method error**

All measurements on the lateral cephalogram were done twice by the same examiner to minimize the error of measurements. Assessment of the intra-examiner reliability analysis was performed using Kappa statistics and was found to be Kappa = 0.80 – 1.00 ($p$< 0.001) which shows perfect agreement according to Landis and Koch (1997).

**Statistical analysis**

After evaluating all the values, the pre-treatment and post treatment measurements using orthodontic mini-implants were compared and statistically analyzed using SPSS (Statistical package for social sciences) software version 21. Student's paired t-tests were used to describe and compare the data. The level of statistical significance used in this study was set at $p<0.05$.

**Results**

The following results were obtained after statistically analyzing the data using SPSS software. Student's paired t-test was used to describe and compare the data and all the variables were calculated as mean and standard deviation. Table II shows the comparison of pre-treatment and post treatment mean values of the parameters used in the study. Table III shows the comparison of measurements of pre-treatment and treatment changes using Student's paired t-test test.

**Fig 1:** Template soldered on archwire for positioning of mini implant

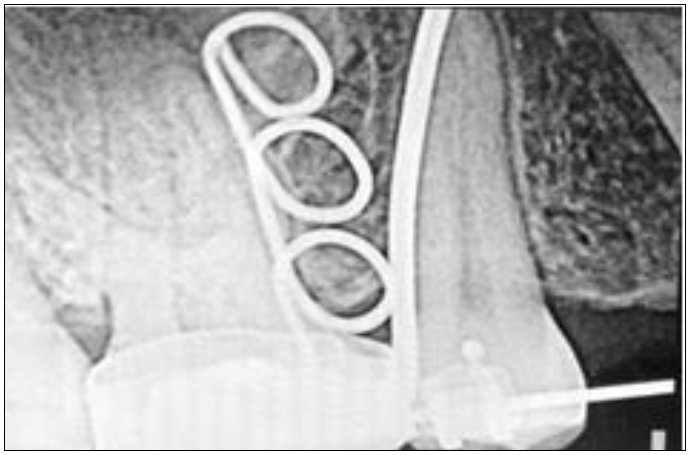

**Fig 2:** Intraoral periapical view of the soldered template

**Fig 3:** Intra oral periapical view to check mini implant position

**Fig 4:** Mini implant position between second premolar and first molar

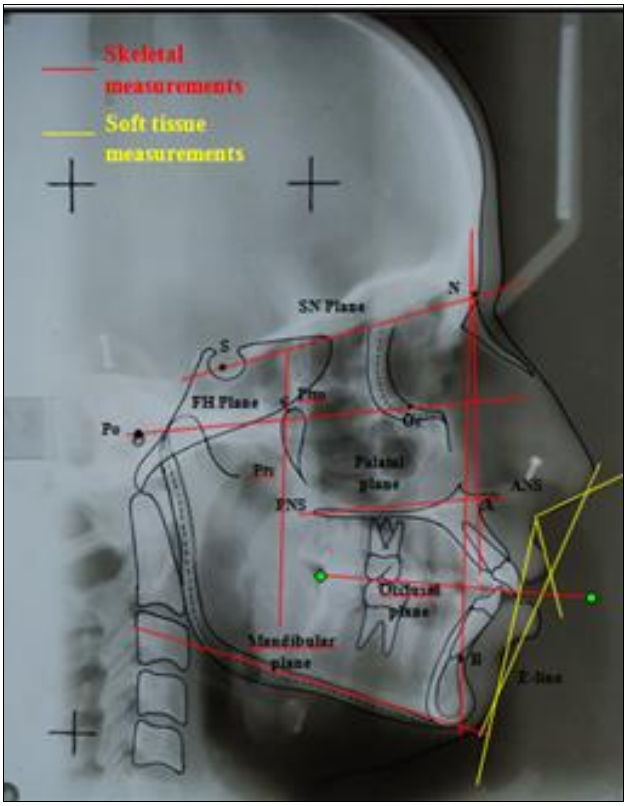


**Fig 5(A):** Lateral Cephalogram showing skeletal and soft tissue parameters

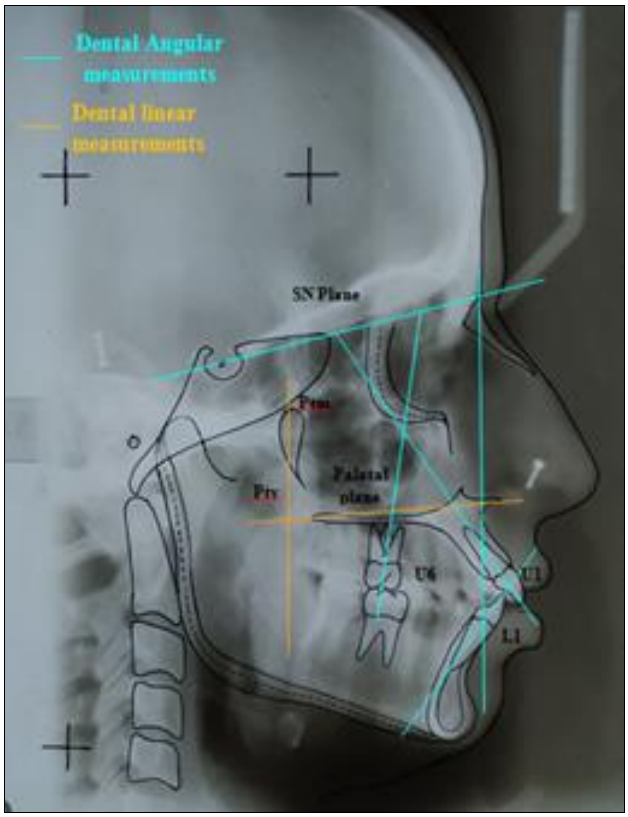


**Fig 5(b):** Lateral cephalogram showing dental linear and angular parameters

**(A): Right lateral view** **(B): Left lateral view**

**Fig 6:** Mid treatment intraoral photographs of patient treated with orthodontic mini implants


**Fig 7:** Comparison of pre-treatment and post treatment extra oral photographs of patient treated with orthodontic mini implants


**Fig 8:** Comparison of pre-treatment and post treatment intra oral photographs of patient treated with orthodontic mini implants

## Discussion

Closure of extraction spaces is one of the most important steps in orthodontic treatment which is routinely performed in clinical orthodontics. It is the most important processes in orthodontics for achieving an ideal occlusion and without adequate knowledge of treatment mechanics; it can result in failure to achieve stable results. As the main aim of the treatment is to achieve the desired tooth position while keeping in consideration the side effects which various retraction mechanics can cause, mini implants have come into use.

Even without patient compliance, they provide stationary anchorage for various tooth movements. The line of force can be made to pass through the centre of resistance of the anterior segment, thereby resulting in more bodily movement and reducing the chances of uncontrolled tipping and thus anchor loss. It provides more predictable and stable results in case of absolute anchorage of the posterior teeth. Hence, the present study was done to compare the dentoalveolar, skeletal & soft tissue changes produced by orthodontic mini implant during en masse retraction.

The results of the present study showed that on comparison of the mean values of SNA statistically significant difference ($p<0.05$) were seen in SNA angle because the horizontal force axis was located at 6mm above the arch wire which resulted in the bodily movement of the upper incisors. The retraction of the anterior teeth with bodily movement is known to produce more remodelling at point A. The results of our study was in accordance with the study done by Sibaie *et al*. (2013) [7], they found that the retraction of anterior teeth with bodily movement produced more remodelling of bone at point A than tipping movement.

Further, the results of the present study showed that there was no significant change in SNB angle because retraction in the mandibular arch was done using sliding mechanics. This was in accordance to the study done by Liu *et al*. (2009) [8], they also used mini-implants in the upper arch and sliding mechanics in the lower arch.

Significant decrease in the ANB angle and A-PTV was due to more bodily movement of the anterior teeth resulting in bone remodelling changes at point A as compared to tipping movements observed commonly in friction and frictionless mechanics. This was in accordance to the study done by Liu *et al*. (2009) [8] and Kuroda *et al*. (2009) [9], they also observed significant difference in the ANB angle when using the mini-implants.

The mean values of SN-OP, FMA and ANS-Me showed no change because the position of the mini-implant and the J hook were at the same level which resulted in no intrusion or extrusion of the maxillary molars, therby not having any effect on the occlusal and mandibular plane. The results of the present study were in accordance with the study done by Park *et al*. (2008) [10].

The dental effects produced by different treatment mechanics showed that the linear distance from upper central incisor to Pterygoid vertical (U1-PTV) and U6-PTV showed statistically significant difference ($p<0.05$). This might be because the closure of the extraction space was completely done by the distalization of the anterior segment as the source of anchorage was skeletal which prevents the loss of anchorage. This was in accordance to the study done by Park *et al*. (2008) [10] and Basha *et al*. (2010) [11].

Moreover, the mean value of U1-PP and U6-PP was found to be statistically insignificant i.e ($p<0.05$) which show that there were minimal changes in the vertical dimension of incisors and molars, this might be due to the fact that mini-implants provide an adequate stable source of skeletal anchorage for en masse retraction and prevent undesired incisor and molar tipping. This was in accordance to the study done by Hedayati *et al*. (2016) [12] and Rhee *et al*. (2001) [13].

On evaluation of the mean values of the inclination of upper incisor U1-SN, U1-NA (linear and angular) and interincisal angle (U1-L1) were found to be statistically significant ($p<0.05$). The proclamation and protrusion of upper incisors decreased in relation to the cranial base and NA plane because of more bone remodelling at point A and also due to minimal anchor loss which resulted in closure of extraction space entirely by the retraction of anterior segment and thus significantly decreasing the incisor protrusion and proclination. The results of the study were in accordance with the study done by Basha *et al*. (2010) [11] and Park *et al*. (2008) [10], they also found that the incisor protrusion decreased when incisor retraction was done and was maximum in the implant group.

Also, the mean values of upper molar to SN plane (U6-SN) was found to be statistically insignificant ($p<0.05$). The maxillary first molar remained stable and upright throughout the retraction phase because the source of anchorage was skeletal. The results of our results were in accordance to the study reported by Upadhyay *et al*. (2008) [14].

On evaluation of the effect of retraction on the soft tissue, the mean value of upper lip to E-line and upper lip protrusion (SnP-UL) and Nasolabial angle was found to be statistically significant ($p<0.05$). It has been believed that the upper lip follows the inclination of the upper incisors, as orthodontic mini-implants resulted in maximum retraction of incisors so the retraction of the upper lip was also maximum This was in accordance with the study done by Park *et al*. (2008) [10] and and Kuroda *et al*. (2009) [9], they also concluded that retraction of the incisors resulted in the retraction of the upper lip, thereby reducing the upper lip protrusion.

When the comparison of the measurements of the pre-treatment and the treatment changes were done, it was found that the orthodontic mini implants did not show any significant differences in : SNA, SNB, ANB and SN-OP ($p<0.05$), but showed decreased A-PTV distance , normal FMA, normal lower anterior facial height , maximum retraction of the upper incisors (U-PTV, U1-NA, U1-SN, U1-L1), minimum anchor loss (U6-PTV, U6-SN), minimal extrusion of molars (U6-PP), minimal intrusion of upper incisor(U1-PP) and maximum improvement in the soft tissue profile( upper lip- E line, SnP-UL, nasolabial angle) ($p<0.05$).

It seems that en masse retraction with mini implants not only eases the biomechanics involved but also controls the undesired tooth movements in the anterio-posterior and vertical dimensions in the anterior and posterior segments due to the possibility of passing the force axis close to the centre of resistance of maxillary anterior teeth. Orthodontic mini implants did not require patient's cooperation to reinforce anchorage and provided more significant improvement of facial profile than that observed with traditional anchorage mechanics.

**Table 1:** Dental, skeletal and soft tissue measurements used in the study

| | | |
|---|---|---|
| **A. Skeletal Measurements [Figure 5(A)]** | | |
| 1. | SNA (°) | Angle formed between sella- nasion plane and the line joining nasion to point A |
| 2. | SNB (°) | Angle formed between sella- nasion plane and the line joining nasion to point B |
| 3. | ANB (°) | Angle formed between the line joining nasion to point A and the line joining nasion to point B. |
| 4. | A-PTV (mm) | Linear distance from point A to pterygoid vertical plane |
| 6. | SN-OP angle (°) | Angle formed between sella-nasion plane to occlusal plane |
| 7. | FMA (°) | Angle formed between frankfort mandibular plane and the inferior border of mandible |
| 8. | ANS to Me(mm) | Linear distance from anterior nasal spine to menton |
| **B. Dental Linear Measurements [Figure 5(B)]** | | |
| 1. | U1-PTV (mm) | Linear distance from the labial surface of upper incisor to pterygoid vertical plane |
| 2. | U6-PTV (mm) | Linear distance from the mid-point of the crown of upper molar to pterygoid vertical plane. |
| 3. | U1- PP (mm) | Linear distance from the incisal edge of upper incisor to palatal plane |
| 4. | U6-PP (mm) | Linear distance from the mid-point of the crown of upper molar to palatal plane |
| 5. | U1-NA (mm) | Linear distance from the long axis of upper incisor to N-A line |
| **C. Dental Angular Measurements [Figure 5(B)]** | | |
| 1. | U1-SN(°) | Angle formed between the long axis of upper incisor to sella-nasion plane |
| 2. | U1- NA(°) | Angle formed between the long axis of upper incisor to N-A line |
| 3. | U6-SN(°) | Angle formed between the mid-point of crown of upper molar to sella-nasion plane |
| 4. | U1-L1(°) | Angle formed between the long axis of upper incisor to the long axis of lower incisor |
| **D. Soft Tissue Measurements [Figure 5(A)]** | | |
| 1. | UL-E line (mm) | Linear distance from the upper lip and E line |
| 2. | SnP- UL (mm) | Linear distance from subnasale to soft tissue pogonion |
| 3. | Nasolabial Angle (°) | Angle formed between the tangent to the base of nose & tangent to the upper lip. |

**Table 2:** Comparison of Pre-treatment and post treatment mean values of the parameters used in the study

| Parameters | Pre-treatment | Post-treatment | Test of Significance | |
|---|---|---|---|---|
| | Mean± SD | Mean± SD | t value | p value |
| **Skeletal** | | | | |
| SNA (º) | 82.7±0.63 | 80.9±0.73 | -2.51 | 0.02* |
| SNB (º) | 78.7±1.41 | 78.0±1.49 | 1.27 | 0.21 |
| ANB (º) | 3.1±0.73 | 2.0±0.66 | 2.82 | 0.01* |
| A-PTV (mm) | 45.5±3.38 | 43.6±3.68 | 2.10 | 0.01* |
| SN-OP (º) | 20.3±1.41 | 20.7±1.25 | 1.28 | 0.21 |
| FMA (º) | 27.4±2.22 | 27.4±2.63 | 0.00 | 1 |
| ANS-Me (mm) | 70.9±2.99 | 70.8±2.52 | 0.428 | 0.678 |
| **Dental Linear** | | | | |
| U1-PTV (mm) | 50.6±2.22 | 43.7±2.45 | 8.104 | 0.0002*** |
| U6-PTV (mm) | 24.6±2.06 | 24.0±2.41 | 0.00 | 1 |
| U1-PP (mm) | 29.2±0.91 | 29.0±0.99 | 1.405 | 0.19 |
| U6-PP (mm) | 24.5±2.22 | 24.9±2.07 | 3.10 | 0.05 |
| U1- NA (mm) | 9.1±0.98 | 4.6 ±0.56 | 3.41 | 0.001** |
| **Dental Angular** | | | | |
| U1-SN (º) | 112.1±1.37 | 100.0±1.03 | 14.72 | 0.0001*** |
| U1-NA (º) | 33.58±0.24 | 24.23 ±0.36 | 13.60 | 0.0001** |
| U6-SN (º) | 70.3±1.15 | 70.8±1.12 | 3.43 | 0.06 |
| U1-L1 (º) | 109.1±1.72 | 130.4±1.89 | -19.08 | 0.0001*** |
| **Soft Tissue** | | | | |
| UL – E LINE (mm) | 4.2±1.03 | 1.0±1.05 | 2.54 | 0.01* |
| SnP- UL (mm) | 10.80±0.78 | 6.1±0.82 | 2.74 | 0.01* |
| Nasolabial Angle (º) | 89.9±3.06 | 102.4±1.16 | 2.10 | 0.02* |

$p<0.05$ * statistically significant; $p<0.001$** statistically highly significant; $p<0.0001$*** statistically very highly significant

**Table 3:** Comparison of measurements of pre-treatment and treatment changes after en-masse retraction using orthodontic mini implants

| Parameters | Pre-treatment | Treatment changes | p value |
|---|---|---|---|
| **Skeletal** | | | |
| SNA (º) | 82.7±0.63 | -1.8±0.45 | 0.06 |
| SNB(º) | 78.7±1.41 | -0.7±1.15 | 0.06 |
| ANB (º) | 3.1±0.73 | -1.1±0.25 | 0.09 |
| A-PTV (mm) | 45.5±3.38 | -1.9±2.10 | 0.04* |
| SN-OP (º) | 20.3±1.41 | 0.40±1.10 | 0.25 |
| FMA (º) | 27.4±2.22 | -0.00±0.80 | 0.04* |
| ANS-Me (mm) | 70.9±2.99 | -0.1±1.18 | 0.04* |
| **Dental linear** | | | |
| U1-PTV (mm) | 50.6±2.22 | -6.9±1.80 | 0.02* |
| U6-PTV (mm) | 24.6±2.06 | 0.60±1.98 | 0.04* |
| U1-PP (mm) | 29.2±0.918 | 0.20±1.00 | 0.02* |

| | | | |
|---|---|---|---|
| U6-PP (mm) | 24.5±2.22 | 0.40±1.89 | 0.01* |
| U1-NA (mm) | 9.1±0.98 | -4.5±0.75 | 0.03* |
| **Dental angular** | | | |
| U1-SN(º) | 112.1±1.37 | -12.1±1.05 | 0.03* |
| U1-NA (º) | 33.58±0.24 | -9.35±0.10 | 0.03* |
| U6-SN (º) | 70.3±1.15 | 0.50±1.08 | 0.04* |
| U1-L1 (º) | 109.1±1.72 | 21.3±1.50 | 0.03* |
| **Soft tissue** | | | |
| UL – E LINE (mm) | 4.2±1.03 | -3.2±0.89 | 0.03* |
| SnP- UL (mm) | 10.80±0.78 | -4.7±0.45 | 0.02* |
| Nasolabial angle (º) | 89.9±3.06 | 12.5±2.75 | 0.04* |

$p<0.05$ * statistically significant; $p<0.001$** statistically highly significant; $p<0.0001$*** statistically very highly significant

## Conclusion

1. The patients treated with orthodontic mini implants showed significant changes in the dental, skeletal and soft tissues parameters with maximum retraction of the upper incisors, minimal extrusion of molars and intrusion of upper incisors; minimal change in FMA and lower anterior facial height.
2. The orthodontic mini implants showed negligible amount of anchor loss.
3. An excellent improvement in the soft tissue profile of the patient was observed.

## Acknowledgements

- **Source (s) of Funding:** Self
- **Conflicting Interest:** None Declared
- **Source(s) of support:** Self
- **Conflicting Interest:** None
- Ethical approval was taken from the ethical committee of Himachal Dental College, Sundernagar prior to commencing the study.
- The consent for the publication of this article has been taken from all the contributing authors.

## References

1. Rizk MZ, Mohammed H, Ismael O, Bearn DR. Effectivness of en masse versus two-step retraction: A systemic review and meta-analysis. Prog Orthod Jan 5 2018;18(1):41.
2. Chopra SS, Mukherjee M, Mitra R, Kochar GD, Kadu A. Comparative evaluation of anchorage reinforcement between orthodontic implants and conventional anchorage in orthodontic management of bimaxillary dentoalveolar protrusion. Medical journal armed forces India; c2016.
3. Davis D, Krishnaraj R, Duraisamy S, Dilip S, Charle A. Comparison of Rate of Canine Retraction and Anchorage Potential between Mini-implant and Conventional Molar Anchorage: An *In vivo* Study. Contemporary Clinical Dentistry. July-September 2018;9(3):337.
4. Sharma K, Sangwan KS. Micro-Implant Placement Guide: Annals of Medical and Health Sciences Research, Sep-Oct 2014;4(Special Issue 3):326-328.
5. Carano A, Velo S, Leone P, Siciliani G. Clinical applications of the miniscrewappliance. JCO. 2005 Jan;39(1):9-30.
6. Hedayati Z, Shomali M. Maxillary anterior en masse retraction using different antero- posterior position of mini screw: A 3D finite element study. Progress in orthodontics. 2016;17(1):1-7.
7. Sibaie SA, Hajeer MY. Assessment of changes following en-masse retraction with mini-implants anchorage compared to two-step retraction with conventional anchorage in patients with class II division 1 malocclusion: a randomized controlled trial. The European Journal of Orthodontics; c2013 June.
8. Liu YH, Ding WH, Liu J, Li Q. Comparison of the differences in cephalometric parameters after active orthodontic treatment applying mini – screw implants or transpalatal arches in adult patients with bialveolar dental protrusion. Journal Of Oral Rehabilitation. 2009;36(9);687-695.
9. Kuroda S, Yamada K, Deguchi T, Kyung HM, Yamamoto TT. Class II malocclusion treated with miniscrewanchorage: Comparison with traditional orthodontic mechanics outcomes. American Journal Of Orthodontics And Dentofacial Orthopedics. March 2009;135(3):302-309.
10. Park HS, Kwon TG. Sliding Mechanics with Microscrew Implant Anchorage. Angle Orthodontist. 2004;74(5):703-710.
11. Basha AG, Shantaraj R, Mogegowda SB. Comparative study between conventional En-Masse Retraction (Sliding Mechanics) and En –Masse Retraction Using Orthodontic micro- implant. Implant Dentistry. 2010;19(2):128-136.
12. Hedayati Z, Shomali M. Maxillary anterior en masse retraction using different antero- posterior position of mini screw: A 3D finite element study. Progress orthod, Dec 2016;17(1):1-7.
13. Rhee JN, Chun YS, Row J. A comparison between friction and frictionless mechanics with a new typodont simulation system. Am J Orthod Dentofacial Orthop. April 2001;119(3);292-9.
14. Upadhyay M, Yadav S, Patil S. Mini –implant anchorage for en –masse retraction of maxillary anterior teeth: A clinical cephalometric study American Journal Of Orthodontics and Dentofacial Orthopedics. 2008;134(6):803-810.