



ISSN Print: 2394-7489  
ISSN Online: 2394-7497  
IJADS 2022; 8(4): 73-78  
© 2022 IJADS  
[www.oraljournal.com](http://www.oraljournal.com)  
Received: 01-08-2022  
Accepted: 03-09-2022

**Dr. Akshay Ghai**  
BDS, Dr Harvansh Singh Judge  
Institute of Dental Sciences and  
Hospital, Panjab University,  
Chandigarh, Panjab, India

**Dr. Neeraj Sharma**  
Professor, Oral Medicine and  
Radiology, Dr Harvansh Singh  
Judge institute of Dental  
Sciences and Hospital, Panjab  
University, Chandigarh, Panjab,  
India

## Tubercular osteomyelitis of mandibular condyle in a pediatric patient

**Dr. Akshay Ghai and Dr. Neeraj Sharma**

DOI: <https://doi.org/10.22271/oral.2022.v8.i4b.1627>

### Abstract

Tuberculosis is a chronic granulomatous bacterial infection caused most commonly by *Mycobacterium* species. Extrapulmonary tuberculosis (EPTB) of the mandibular condyle is rare and presents with alteration of the condylar morphology along with extra-oral swelling. EPTB can either be a primary or a secondary source of infection i.e. disseminated from other organs. We represent a case of a 7 - year- old male with EPTB of the mandibular condyle causing osteomyelitis with uneventful healing. Ill-defined radiolucency of the mandibular condyle on radiographs should include tuberculosis as a differential diagnosis.

**Keywords:** Tuberculous osteomyelitis, TMJ tuberculosis, pediatric tuberculosis

### Introduction

Tuberculosis (TB) still remains a global health problem and a major cause of death in developing countries. Poverty, economic recession, malnutrition and multi drug resistance are the attributing factors for its high prevalence with India being one of the 14 high-burden countries<sup>[1]</sup>.

TB is a chronic granulomatous infection of bacterial origin. The causative organism is *Mycobacterium*, a strict aerobic microorganism first described by Robert Koch. It can be pulmonary or extra pulmonary TB [EPTB]. Primary TB of pulmonary origin presents with cough with sputum, hemoptysis, evening rise of fever, loss of appetite, dyspnoea. EPTB is TB of organs other than the lungs and its prevalence rate is nearly 20% of all cases with 5-10% occurring in maxillofacial region. 4-5% of all cases of TB are osteoarticular<sup>[2]</sup>. The diagnosis of EPTB in the pediatric age is a challenge, since it presents with insidious onset without any constitutional signs and symptoms in up to 72% cases<sup>[2]</sup>.

We report a case of TB in the mandibular condyle in a young boy. The aim is to lay emphasis on correct diagnosis and to include TB as a differential in osteolytic lesions of mandibular condyle.

### Case Presentation

A 7-year-old male patient was referred to the department of Oral Medicine and Radiology for evaluation of a slow growing, progressively increasing swelling in front of the right ear for the past 1-month (Fig. 1). The patients' medical history was non-contributory. There was no history of trauma to the TMJ region or dental infection. The patient was afebrile and well nourished at the time of examination. The patients' guardian did not report of any evening rise of fever, weight loss, coughing or chest pain. He had been vaccinated with BCG. The patient's father had a tuberculosis infection from which he had recovered 2 months back.

On palpation the swelling was firm, asymmetrical, non-tender, non-fluctuant with normal overlying skin. There was no evidence of regional lymphadenopathy. TMJ movements were within normal range without evidence of clicking, crepitation and trismus. On an intraoral examination, the teeth were in good condition and there was no intraoral swelling or ulcer.

A panoramic radiograph revealed a mixed dentition stage with no malocclusion or alteration in the development of dentition. Ill-defined margins over the right mandibular condyle with de-corticated borders resulting in altered condylar morphology were noted (Fig. 2).

**Corresponding Author:**  
**Dr. Neeraj Sharma**  
Professor, Oral Medicine and  
Radiology, Dr Harvansh Singh  
Judge institute of Dental  
Sciences and Hospital, Panjab  
University, Chandigarh, Panjab,  
India

A differential diagnosis of osteomyelitis, juvenile idiopathic arthritis, Langerhans cell histiocytosis, autoimmune diseases, malignancy was made.

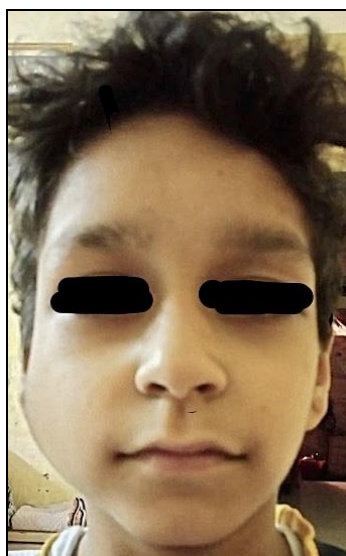Laboratory investigations revealed increased erythrocyte sedimentation rate (ESR; 38 mm/hr). CT Scan was performed subsequently. CT Scan showed ill-defined margins of the right condyle with heterogeneous enhancement of the surrounding musculature and juxta cortical abscess. Periosteal bone reaction could be seen both on the medial as well as the lateral aspect of the right condyle (Fig. 3 a,b,c,d). Radiographic findings of destructive and reactive sclerotic changes were compatible with chronic infection or malignancy.

Montoux test was performed using 0.1 ml (5 tuberculin units) of purified protein derivative (PPD) being injected intradermally on the forearm using a 26-gauge needle. The values were read 48 hours later. A positive reaction measuring 21 X 22 mm was noted (Fig. 4). ELISA (enzyme linked immunosorbent assay) HIV 1 and 2 was negative. His chest radiograph revealed clear lung fields.

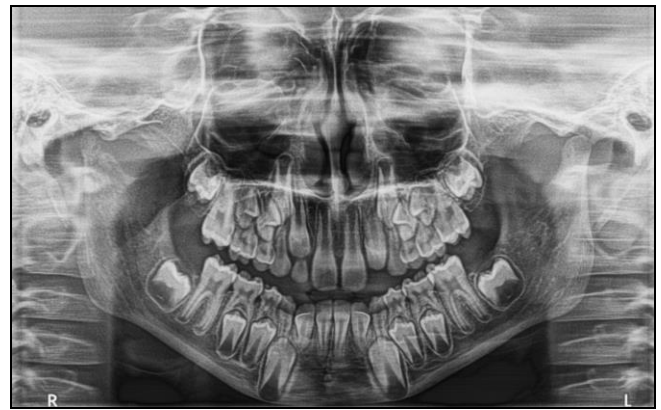FNAC from the preauricular region yielded a very small sample, which was sent for fluorescence microscopy with Auramine – O and turned out to be positive for mycobacteria (Fig 5).

A final diagnosis of TB osteomyelitis of mandibular condyle was made and in consultation with the physician the patient was started with Anti Tubercular Treatment (ATT) according to Short Course Guidelines. Phase I or intensive phase drug regimen consisting of Rifampicin, Isoniazid, Ethambutol, and Pyrazinamide was given for 2 months. The patient reported with decrease in swelling within 4 weeks of therapy. He was continued on phase II or continuation phase with Isoniazid, Rifampicin and Ethambutol for 4 months. Follow up was continued for 9 months and there was complete resolution of swelling.

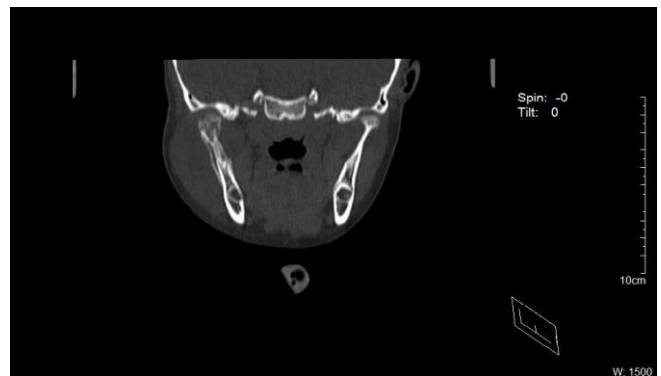
After 12 months of treatment, a panoramic radiograph was taken to re-evaluate the status of the condyle. OPG revealed uneventful healing with an altered, flattened right condyle (Fig. 6). The dentition was developmentally and functionally normal with no evidence of any developing malocclusion. The patient was pain-free during recall examinations.



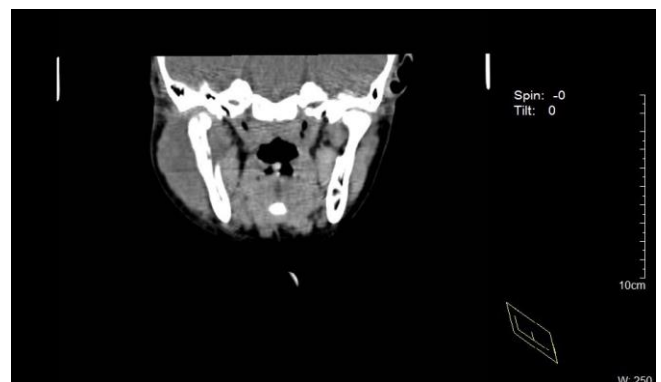**Fig 1:** Clinical Picture Extra oral swelling on the right side of the face



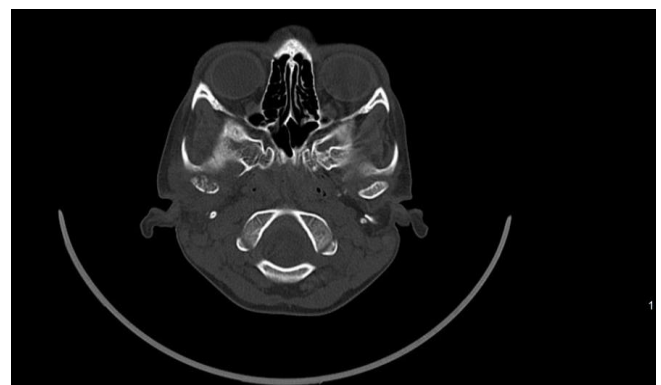
**Fig 2:** Orthopantomogram Ill defined margins of the right condyle with loss of cortication



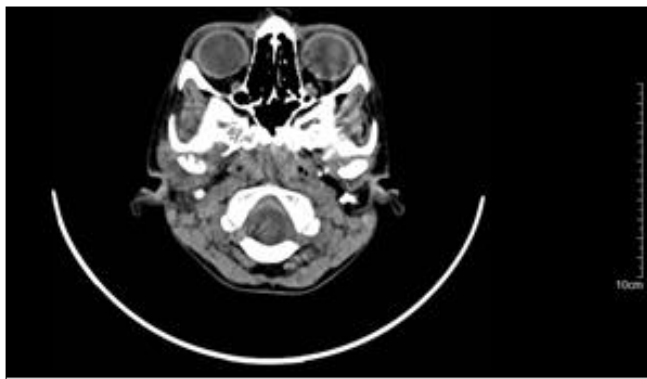
**Fig 3a:** Coronal Bone Window Evidence of periosteal bone reaction on mesial and lateral aspect of the ramus of the mandible along with loss of cortication of right condyle



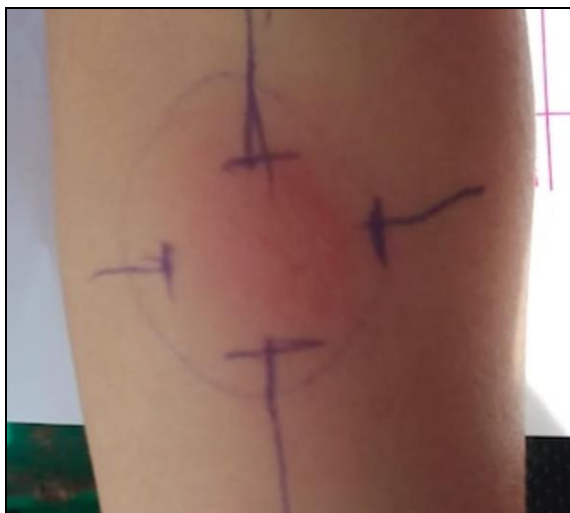**Fig 3b:** Coronal Soft window Heterogeneous enhancement of the musculature especially in relation to medial pterygoid and masseter muscle



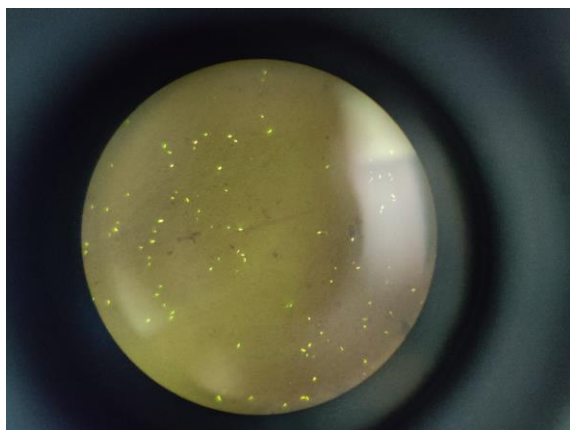
**Fig 3c:** Axial Bone window Loss of cortication of right condyle. It can be compared with the antagonist condyle.



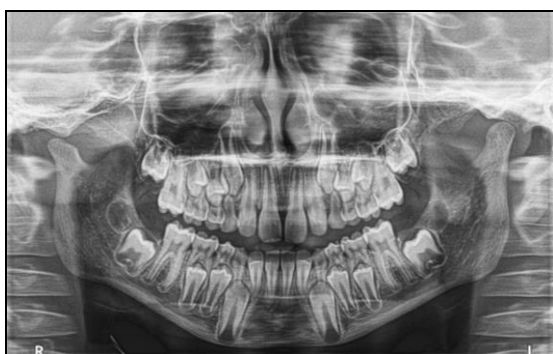**Fig 3d:** Axial Soft Tissue window Erosion of the right condyle with enhancement of the soft tissue



**Fig 4:** Picture of forearm showing a positive Montoux test



**Fig 5:** Fluorescent microscopy with Auramine-O positive for Mycobacterium Tuberculosis



**Fig 6:** Post Operative Orthopantomogram

## Discussion

TB is caused by the air-borne bacillus *M. tuberculosis* and less commonly by *M. bovis*, *M. africanum* [3]. Primary infection usually occurs in the lungs and rarely in the pharyngeal tonsils [4], lymph nodes, bones and salivary glands. It can then spread to other areas of the body via the blood stream [4]. Presentation of TB in the maxillofacial region can be in forms of unhealed sockets, ulcerations, cold abscess where the usual signs of inflammation, such as heat and erythema are absent [5].

Epidemiologically in 2019, WHO reported that 10 million people fell ill with TB worldwide, out of which 12% were children <15 years of age [1]. Universally, TB is one of the top 10 causes of death especially in HIV patients as an opportunistic infection [1].

Children (<15 years) account for approximately 14% of all TB deaths, and 11% of all TB cases had uneventful healing.<sup>1</sup> Osteoarticular tuberculosis (OA TB) has a variable incidence in endemic and non-endemic areas of the world [6]. Here, the tubercle bacilli become facultative anaerobes due to reduction in oxygen tension and thus are less active (paucibacillary) [7]. Roughly 40% child and adolescent TB is often overlooked by health providers, partially accounting for the high infection and mortality rates in this population.

Skeletal TB, which comprises of 1-2% of all TB cases is mostly seen in children [8]. The main route of infection is through haematogenous spread from a primary source/site that is often unknown. The most common sites affected are vertebrae, epiphysis and diaphysis of the long bones radius, tibia, bones of hands, xiphosis. Joint involvement is usually encountered in major joints like the hip, elbow, knee and ankle [9]. Angle and the alveolus are the areas commonly involved in the mandible [10]. Tuberculous involvement of the temporomandibular joint (TMJ) is extremely uncommon. Very few cases of primary, and secondary TB of the TMJ originating from a fistulous communication from the middle ear have been reported in literature [11].

There are no signs that are pathognomic of a diagnosis of TB of the mandible. Clinical presentation is usually in form of unhealed sockets, loosening of teeth, displaced tooth buds, osteomyelitis [12]. In cases where TMJ is involved, mild, local and constitutional symptoms are usually seen in the form of pain, joint stiffness and swelling. Joint involvement starts as synovitis, then progress to periarticular osteopenia and marginal erosion, and end up with joint destruction [13].

Our patient developed swelling over the preauricular region over a period of few weeks without any constitutional symptoms. The orthopantomogram showed destruction of the cortical borders of mandibular condyle. Radiographically, a differential diagnosis included juvenile arthritis, juvenile idiopathic arthritis (JIA), osteomyelitis, Langerhan cell histiocytosis (LCH), and malignancy. However, the CT scan showed periosteal bone reaction along with condylar erosion, which narrowed down our differential to osteomyelitis and malignancy like Ewings sarcoma.

JIA involves one or more joints, begins before the age of 16 years, persists for more than 6 weeks and is of unknown etiology and pathophysiology. It is a diagnosis of exclusion. The joints involved are usually the knee, wrist, hip or TMJ.<sup>14</sup> It can cause irreversible destructive change within 5 years of diagnosis [15]. In our case, a unilateral joint involvement without any warm, tenderness, pain, restrictive joint movement, clicking was seen.

Ewing's sarcoma (ES) is a highly lethal round cell sarcoma seen in young male patients (between the ages of 5 and 30

years). Radiographically the malignancy produces a diffuse irregular radiolucency with ill-defined margins- a moth eaten destructive radiolucency with or without erosion and cortical destruction or expansion. Sometimes a periosteal reaction in form of an onion skin or “sun-ray” appearance may be elicited [16].

Osteomyelitis of condyle is commonly odontogenic in origin either due to an infected third molar or infection following molar tooth extraction, contiguous spread of infection from the ear. [17, 18] Preauricular pain, tenderness, swelling, pus discharge, trismus, deviation of mandible towards affected side on maximum mouth opening are the common clinical symptoms seen. The infections are usually polymicrobial in nature with isolation of Peptostreptococcus, Staphylococcus, Pseudomonas, Mycobacterium, Acinetobacter and Aspergillus species being reported in literature [17, 18].

Radiographic findings in case of tubercular joint involvement include joint effusion, periarticular osteopenia, cortical irregularity, lytic lesions and periosteal new bone formation [19, 20]. These features were seen in our case also. CT scan is more sensitive than plain radiography in determining the extent of disease and occult abscesses. Here in our case the periosteal bone reaction could only be appreciated on the CT.

As there is a lack of proteolytic enzymes in *M. tuberculosis*, the joint space is often preserved in early disease. Cold abscess formation and sinus tracts may become evident as the disease progresses. End-stage disease is characterized by marked joint destruction and fibrous or bony ankylosis [19, 21].

Fluorescence microscopy using fluorochrome dyes like Auramine-O and Auramine Rhodamine is known to have high degree of sensitivity and specificity and is the preferred method in centers with high workload as it is less laborious [22]. This was the method chosen by us in this case taking into consideration the small sample obtained for investigation and the paucibacillary nature of pediatric TB.

Bone scans with Gallium also play an important role in

patients with OA TB especially to look for clinically silent disease in other parts of the skeleton.

Diagnosis of childhood TB remains an enigma, especially in the absence of clinical signs and symptoms and radiographic presence of concomitant lung lesions as was there in our case. Diagnosis is the most difficult aspect of examining TB in children because in its primary form, it is paucibacillary and bacteriological corroboration is nearly always lacking [23, 24]. FNAC is a useful diagnostic adjunct. In this case FNAC was our choice of investigation as it is adequate for diagnosis and avoids a major surgical operation which would be required to obtain tissue for biopsy. It is also cost effective and can be carried out at outpatient levels.

Aggressive debridement with primary closure has been suggested to prevent recurrence [25]. Since, in our case only limited destruction was seen, we decided to combat the disease using therapeutic intervention only. Our patient recovered completely from the swelling within one month of treatment and he continued with the entire course of chemotherapy.

### Literature Review

A scoping literature review was performed to gain insight into pediatric tuberculosis of the mandible. Demographics, imaging were reviewed. The inclusion criteria for selection of case reports included consisted of neonates-20 years old patients, English- language, publishing date inclusive of ranging from 1980-2022, mandible as the target areas for the lesion, and published listed in Pubmed, Scopus, Google Scholar. The mean age is 9.32 years and Male: Female ratio is 9:4 showing a male predilection. Panoramic view is the main initial diagnostic view with diffuse ill-defined hypodense lesion showcasing loss of cortication as the main finding. Advanced radiographic technique involves CT scan showing erosion of the involved bone with mild periosteal reaction and marked lymphadenopathy suggestive of osteomyelitis.

**Table 1:** Literature review of Radiographic findings in TB of the Mandible in Pediatric patients

| Area                 | Age | Sex | 2D Radiographic Finding  | 3D   |
|----------------------|-----|-----|--|--|
| Condyle [3]          | 12  | M   | Panoramic view -diffuse radiolucency with loss of cortication on the superior and anterior portion of condyle  | CBCT of the Right TMJ - rarefaction and destruction of bone in condyle with discontinuity of the cortical boundary suggestive of perforation and erosion of the condylar head  |
| Condyle [26]         | 20  | M   | Panoramic View-ill-defined area of radiolucency seen in the right condyle<br>Ultrasonic view-condyle and neck of the mandible of the right side showed irregularity with erosions suggestive of abscess formation One lymph node anterior to the tragus on right side was enlarged and hypoechoic  | CT Scan-erosion with comminuted destruction of the right mandibular condyle. In the soft-tissue window with contrast there was abscess formation with peripheral enhancement surrounding the right condyle extending into the right masseter and pterygoid muscles |
| Mandibular Body [27] | 10  | M   | Panoramic radiograph revealed an ill-defined, radiolucent, osteolytic lesion surrounding the developing left permanent second premolar and extending posteroinferiorly up to the permanent left first molar<br>Occlusal radiographic view of the left-side mandible showed a periosteal reaction with the periosteum raised posteriorly in relation to the permanent first and second molars, and anteriorly it had an irregular outline. An “onion peel” appearance of the bone was also noted in relation to the second premolar and the permanent first and second molars | CT findings revealed the presence of a soft tissue mass in the submandibular region with an osteolytic lesion in the body of the mandible on the left side. Left submandibular lymphadenopathy was also noted  |
| Condyle [28]         | 18  | F   | Panoramic view -diffuse radiolucency in the ramus of mandible with loss of cortication on the superior and anterior portion of condyle   | CBCT of the left TMJ showed pronounced rarefaction and destruction of bone in the ramus with discontinuity of the cortical boundary suggestive of perforation and erosion of the condylar head   |
| Condyle [29]         | 3   | M   | Intraoral periapical radiograph showing crypt of first permanent molar seemingly destroyed in the anteroinferior region with the developing tooth drifted superiorly.<br>Panoramic- ill-defined radiolucent osteolytic lesion involving the right body, inferior alveolar canal, basal bone, ramus of mandible and, extending superiorly up to neck of the condyle and sigmoid notch. Mandibular occlusal view showing sclerosing osteitis and onion-peel appearance of the mandible.  | CT scan revealed an expansile multilocular cystic lesion in the right ramus and body region with cortical breaks at places. Sequestrum was also noted suggesting osteomyelitis   |
| Condyle [30]         | 4   | M   | Panoramic Radiograph- Poorly defined radiolucency extending  |  |

|                               |          |   |   |   |
|-------------------------------|----------|---|---|---|
|                               |          |   | postero-inferiorly from the apical region of first molar  |   |
| Body <sup>[31]</sup>          | 4        | M | Panoramic radiograph- ill-defined lytic area extending posteroinferiorly from primary right first molar to permanent right first molar  | CT Scan showing osteolytic lesions of the mandible with bony fragmentation and surrounding soft tissue abscess with right submandibular lymphadenopathy.  |
| Body,Ramus <sup>[20]</sup>    | 15 month | F | Posteroanterior radiograph of the mandible-multilocular radiolucent lesion in the right body and ascending ramus that extended to the coronoid notch. Marked cortical expansion without an obvious periosteal reaction. Oblique view of the right mandible - lesion was situated posterior to the follicle of the first permanent molar |   |
| Body <sup>[32]</sup>          | 8        | F | Lateral-oblique radiograph of the mandible showing bone destruction extending from the canine to the molar region on the left side. loss of density of bone in the first premolar region and the deciduous tooth appears to be "floating".  |   |
| Ramus,Condyle <sup>[33]</sup> | 12       | F | Panoramic view-Proliferative and destructive lesion of left posterior mandible  | CT Scan- Lobulated cystic and solid mass surrounding ramus, condyle, glenoid fossa. Hypertrophic changes of the condyle and periosteal reaction of ramus.   |
| Ramus <sup>[34]</sup>         | 6        | M | Panoramic view -Multilocular radiolucent area in the right ramus  | MRI- expansile lesion in the ramus showing breach of the cortex laterally and apparent extension of abnormal soft tissue beyond the bone limit  |
| Angle <sup>[35]</sup>         | 9        | M |   | Non-contrast CT scan of mandible revealed destruction of inner as well as outer wall of the angle of left mandible due to expansile osteolytic mass lesion. Osteoblastic activity was also seen as new bone formation around the lytic lesion. Breach in periosteum with extension of expansile lesion into surrounding soft tissue was also noted. CT findings were reported as malignant bone tumor |
| Body <sup>[36]</sup>          | 14       | M | Ultrasound neck - Diffusely enlarged right parotid gland with loss of normal echotexture and an enlarged submandibular gland  | Contrast-enhanced computed tomography head axial view showing irregularly thickened cortex with loss of corticomedullary junction with multiple loosened areas showing a breach of the cortex and periosteal reaction with adjacent soft tissue component. central hypoattenuation areas representing central necrosis with periosteal reaction   |

## Conclusion

The diagnosis of OATB in pediatrics is a challenge due to its insidious clinical presentation. Due to the increasing incidence of TB, clinical suspicion should be considered in all osteolytic jaw lesions especially in children. The involvement of the condyle and the mandibular joint may cause serious secondary deformities by arresting the downward and forward growth during the period of skeletal growth. This case report emphasizes that if the lesion is primary and detected early, the disease is completely curable and most of the destructive bony changes can be reversed.

## Conflict of Interest

Not available

## Financial Support

Not available

## References

- World Health Organization. Global Tuberculosis Report; WHO: Geneva, Switzerland; c2020.
- Devrim I, Aktürk H, Bayram N, Apa H, Tulumoğlu S, Devrim F, *et al.* Differences between pediatric extrapulmonary and pulmonary tuberculosis: a warning sign for the future. *Mediterr J Hematol Infect Dis.* 2014;6(1):e2014058.
- Mohad N, Dabir A, Vahanwala J, Padhye M, Patwardhan J. Tuberculous osteomyelitis in condyle of mandible: A case report. *Advances in Oral and Maxillofacial Surgery.* 2021 Apr 1;2:100064. <https://doi.org/10.1016/j.adoms.2021.100064>.
- Das A, Das SK, Pandit S, Basuthakur S. Tonsillar tuberculosis: a forgotten clinical entity. *J Family Med Prim Care.* 2015;4(1):124-126.
- Carter E, Chandarana P, Duggineni S, Nasser N, Bridle C. Case series of extra pulmonary tuberculosis presenting as facial swelling. *BDJ.* 2015;218(9):519-522.
- Agashe VM, Johari AN, Shah M, Anjum *et al.* Diagnosis of Osteoarticular Tuberculosis: Perceptions, Protocols, Practices, and Priorities in the Endemic and Non-Endemic Areas of the World A WAIOT View. *Microorganisms.* 2020;8(9):1312. DOI:10.3390/microorganisms8091312
- Moon MS, Kim SS, Moon HL, Kim DH. Mycobacterium tuberculosis in spinal tuberculosis. *Asian Spine J.* 2017;11(1):138-149.
- Teo HE, Peh WC. Skeletal tuberculosis in children. *Pediatr Radiol.* 2004 Nov;34:853-60. Doi: 10.1007/s00247-004-1223-7.
- Tuli SM. General principles of osteoarticular tuberculosis. *Clin. Orthop. Relat. Res.* 2002;398:11-19.
- Bai S, Sun CF. Tuberculous osteomyelitis of the mandible with diffuse swelling of the floor of the mouth: a case report. *J Oral Maxillofac Surg.* 2014;72(749):e1-749.e6. 10.1016/j.joms.2013.11.030.
- Prasad KC, Sreedharan S, Chakravarthy Y, Prasad SC. Tuberculosis in the head and neck: experience in India. *J Laryngol Otol.* 2007;121(10):979-85.
- Chaudhary S, Kalra N, Gomber S. Tuberculous osteomyelitis of the mandible: a case report in a 4-year-old child. *Oral Surg Oral Med Oral Pathol Oral Radiol Endod.* 2004;97(5):603-606.
- Varango G, Bamba I, Kodo M, *et al.* Osteonecrosis of the hip in sickle-cell disease associated with tuberculous arthritis. *Int Orthop.* 1998;22(6):384-389.
- Hemke R, Nusman CM, van der Heijde DM, *et al.* Frequency of joint involvement in juvenile idiopathic arthritis during a 5-year follow-up of newly diagnosed patients: implications for MR imaging as outcome measure. *Rheumatol Int.* 2015;35(2):351-357. doi:10.1007/s00296-014-3108-x
- Rostom S, Amine B, Bensabbah R, Abouqal R, Hajjaj-Hassouni N. Hip involvement in juvenile idiopathic arthritis. *Clinical rheumatology.* 2008 Jun;27:791-4. Doi: 10.1007/s10067-008-0853-9.
- Krishna KB, Thomas V, Kattoor J, Kusumakumari P. A

- Radiological Review of Ewing's Sarcoma of Mandible: A Case Report with One Year Follow-up. *Int J Clin Pediatr Dent.* 2013;6(2):109-114
17. Chattopadhyay PK, Nagori SA, Menon RP, Thanneermalai B. Osteomyelitis of the mandibular condyle: a report of 2 cases with review of literature 2017;75(2):322-335.
  18. Winslow CP, Dichard A, McGuire K. Osteomyelitis of the temporomandibular joint. *Am J Otolaryngol.* 2009;22(2):142-145.
  19. Morris BS, Varma R, Garg A, *et al.* Multifocal musculoskeletal tuberculosis in children: appearances on computed tomography. *Skeletal Radiol.* 2002;31(1):1-8.
  20. Erasmus JH, Thompson IOC, van der Westhuyzen AJ. Tuberculous osteomyelitis of the mandible: report of a case. *J Oral Maxillofac Surg.* 1998;56:1355-1358.
  21. De Vuyst D, Vanhoenacker F, Gielen J, *et al.* Imaging features of musculo- skeletal tuberculosis. *Eur Radiol.* 2003;13(8):1809-1819.
  22. Patiño S, Alamo L, Cimino M, *et al.* Autofluorescence of mycobacteria as a tool for detection of Mycobacterium tuberculosis. *J Clin Microbiol.* 2008;46(10):3296-3302.
  23. Lanka P, Lanka LR, Krishnaswamy B. Role of fine needle aspiration cytology of lymph nodes in the Diagnosis of cutaneous tuberculosis. *Indian J Tuberc.* 2004;51:131-135.
  24. Franco R, Santana MA, Matos E, Sousa V, Lemos ACM. <sup>[1]</sup><sub>SEP</sub> Clinical and radiological analysis of children and adolescents with tuberculosis in Bahia, Brazil. *BJID.* 2003;7:73-81.
  25. Sharma S, Juneja M, Garg A. Primary tubercular osteomyelitis of the sternum. *Indian J Pediatr.* 2005;72(8):709.
  26. Sheikh S, Pallagatti S, Gupta D, Mittal A. Tuberculous osteomyelitis of mandibular condyle: a diagnostic dilemma. *Dentomaxillofac Radiol.* 2012;41(2):169-174.
  27. Dinkar AD, Prabhudessai V. Primary tuberculous osteomyelitis of the mandible: a case report. *Dentomaxillofac Radiol.* 2008;37(7):415-420.
  28. Karjodkar F, Saxena VS, Maideo A, Sontakke S. Osteomyelitis affecting mandible in tuberculosis patients. *J Clin Exp Dent.* 2012;4(1):e72-e76.
  29. Sambyal SS, Dinkar AD, Jayam C, Singh BP. Primary tuberculous osteomyelitis of the mandible in a 3-year-old child. *BMJ Case Rep.* 2016;2016:bcr2016216854.
  30. Bhatt AP, Jayakrishnan A. Tuberculous osteomyelitis of the mandible: a case report. *Int J Paediatr Dent.* 2001;11(4):304-308.
  31. Chaudhary S, Kalra N, Gomber S. Tuberculous osteomyelitis of the mandible: a case report in a 4-year-old child. *Oral Surgery, Oral Medicine, Oral Pathology, Oral Radiology, and Endodontology.* 2004;97(5):603-606.
  32. Nwoku LA, Kekere-Ekun TA, Sawyer DR, Olude OO. Primary tuberculous osteomyelitis of the mandible. *Journal of Maxillofacial Surgery.* 1983;11:46-48.
  33. Lachenauer CS, Cosentino S, Wood RS, Yousefzadeh DK, McCarthy CA. Multifocal skeletal tuberculosis presenting as osteomyelitis of the jaw. *Pediatr Infect Dis J.* 1991;10(12):940-944.
  34. Kothari P, Bartella L, Carter J, Chan O, Piper K. Tuberculosis of the mandible in a child. *J Laryngol Otol.* 1998;112(6):585-587.
  35. Gupta MK, Singh M. Primary tuberculosis of mandible. *Indian Pediatrics.* 2007;44(1):53.
  36. Kalaiarasi R, Vijayakumar C, Archana R, Natarajan R. Pediatric Primary Tuberculous Osteomyelitis of the Mandible Mimicking Parotitis. *Cureus.* 2018;10(1):e2071.

**How to Cite This Article**

Ghai A and Sharma N. Tubercular osteomyelitis of mandibular condyle in a pediatric patient. *International Journal of Applied Dental Sciences.* Yy;vol(issue):pp.

**Creative Commons (CC) License**

This is an open access journal, and articles are distributed under the terms of the Creative Commons Attribution-NonCommercial-ShareAlike 4.0 International (CC BY-NC-SA 4.0) License, which allows others to remix, tweak, and build upon the work non-commercially, as long as appropriate credit is given and the new creations are licensed under the identical terms.